



TATYASAHEB KORE DENTAL COLLEGE AND RESEARCH CENTRE

NEW PARGAON – 416 113

Tal.: Hatkanangale Dist.:Kolhapur (Maharashtra State)

National Dental Commission

INFORMATION REGARDING INSTITUTIONAL COMPLIANCE



4. Clinical Compliance

4.2 Student clinical work registers are updated regularly.

Mahatma Gandhi Charitable Medical Trust, Warananagar

**TATYASAHEB KORE DENTAL COLLEGE & RESEARCH CENTRE ,
NEW PARGAON**

RECOGNISED BY DENTAL COUNCIL OF INDIA, NEW DELHI

**AFFILIATED TO MAHARASHTRA UNIVERSITY OF
HEALTH SCIENCES, NASHIK**



DEPARTMENT OF
PROSTHODONTICS
RECORD BOOK

NAME *Onehal Salokhe*

PERMANENT REGISTRATION NO. 516811

ROLL NO. 45



Dr. Harish Kulkarni, M.D.S.
Principal
T. K. D. C. & Research Centre,
New Pargaon, Tal: Hatkanangle,
Dist. Kolhapur - 416 137

Mahatma Gandhi Charitable Medical Trust, Warananagar

**TATYSAHEB KORE DENTAL COLLEGE & RESEARCH CENTRE,
NEW PARGAON**

**DEPT. OF PROSTHODONTICS
RECORD BOOK**

CERTIFICATE

This is to certify that shri/Kum. Snehal Vikram
Salokhe Roll No. 45

has satisfactorily carried out the practical work in Department of
Prosthodontics as prescribed by
MAHARASHTRA UNIVESITY OF HEALTH SCIENCES NASHIK
For the year 20 23 -20 24

Handwritten signature and date: 23/11/25

Handwritten signature and date: 23/10/25

S.M. Kothke
Staff in-charge

Handwritten signature
Professor & Head

Dept. Of Prosthodontics

Date :

Name Snehal vikram Salokhe

P.R.N. _____


Roll No. 45

University Examination no. 516811



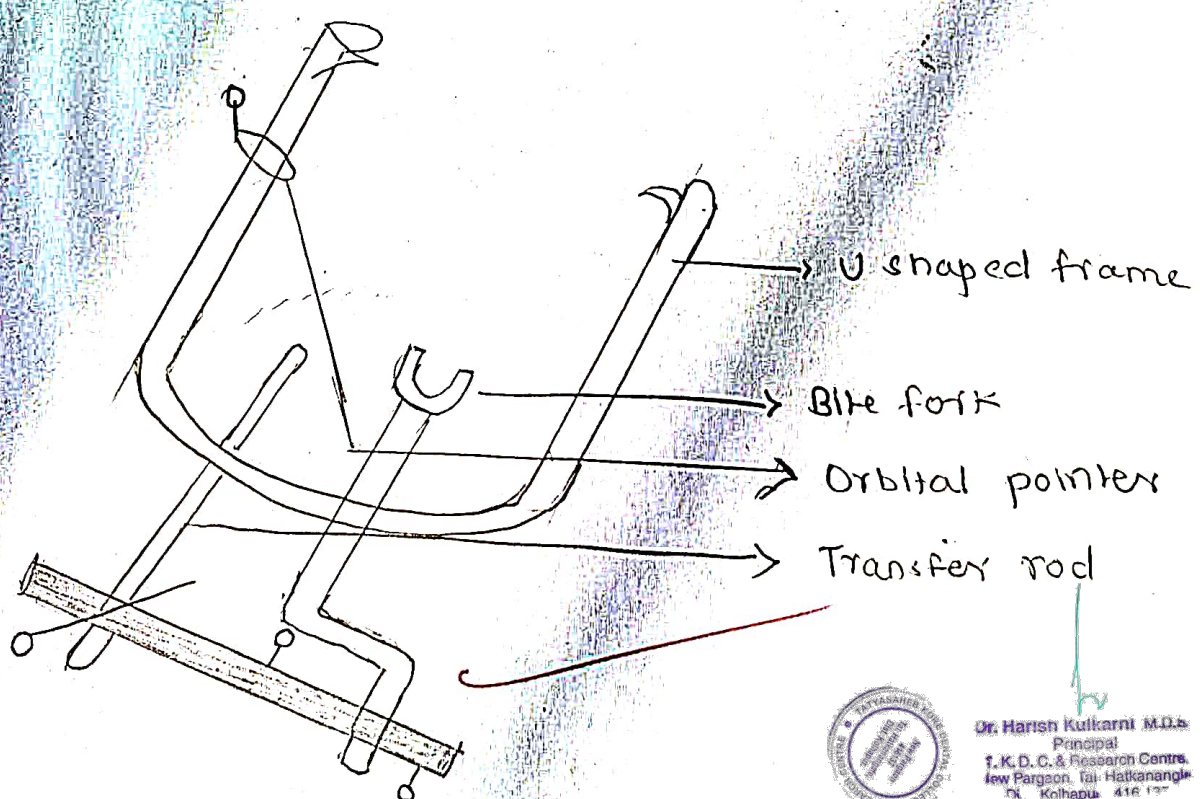
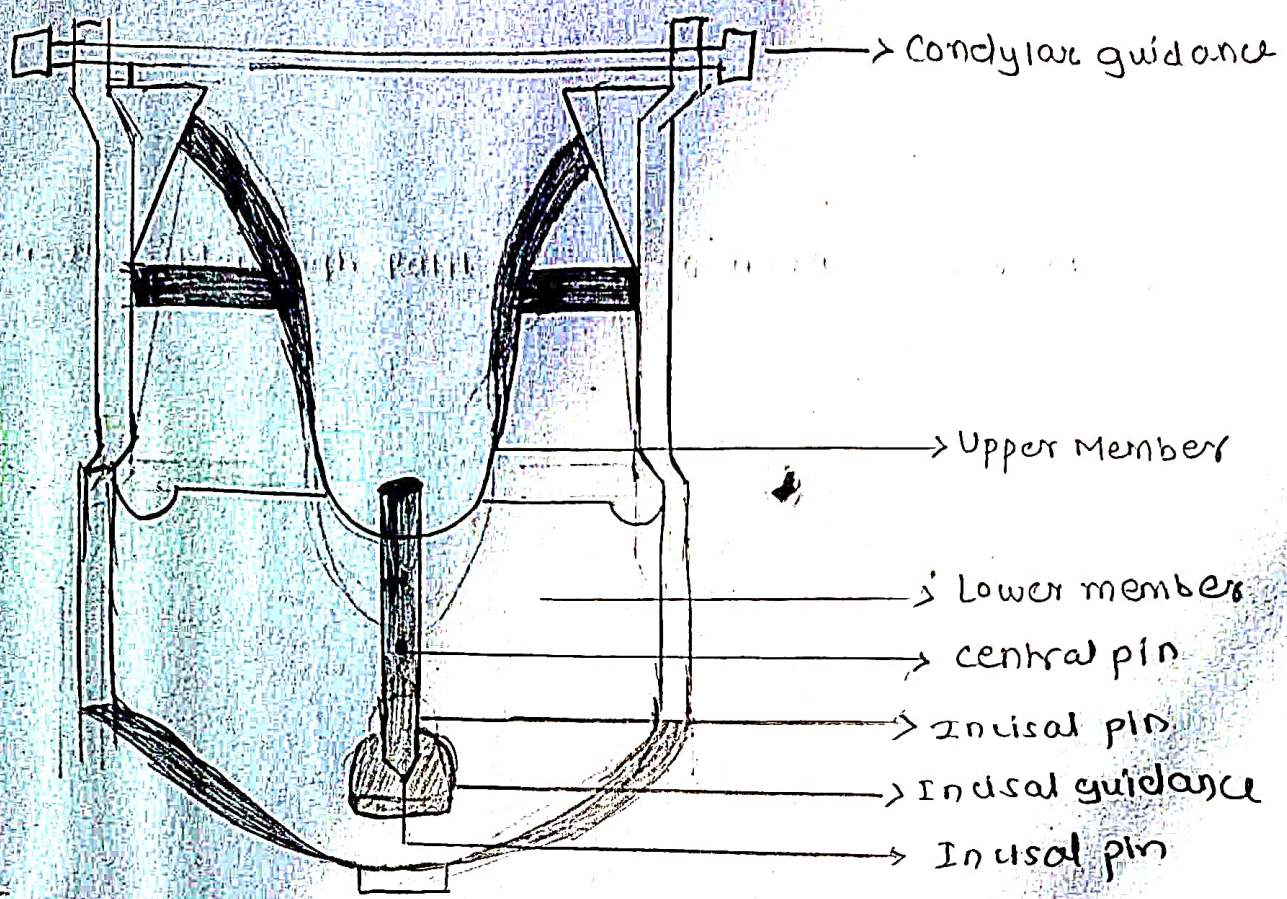
Dr. Harish Kulkarni M.D.S.
Principal
T. K. D. C. & Research Centre,
New Pargaon, Tal: Hatkanangle,
Dist: Kolhapur - 416 137

COMPLETE DENTURE WORK RECORD INDEX

Sr. No.	Date	Patient's Name	Date of Commencement	Date of Completion	Staff Sign.
1	6-4-24	Mansingh Pahl	6-4-24	25-6-24	



Dr. Harish Kulkarni M.D.S.
Principal
T.K.D.C. & Research Centre,
Jew Pargaon, Tal: Halkanangle,
Kolhapur.

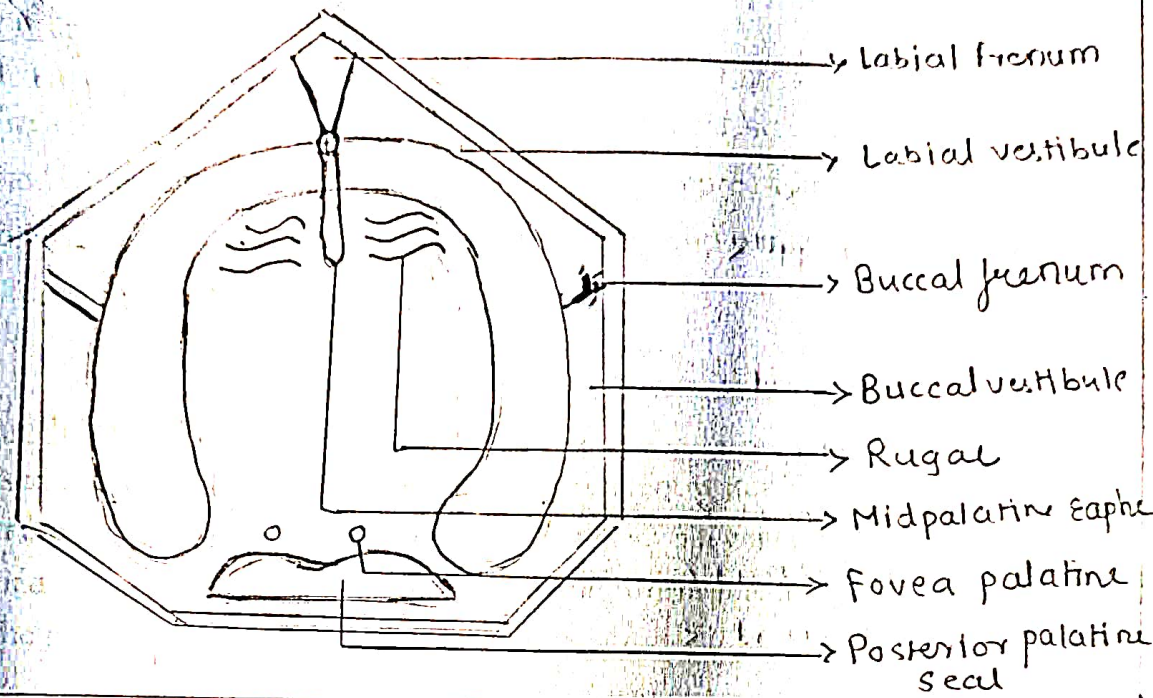


facebow

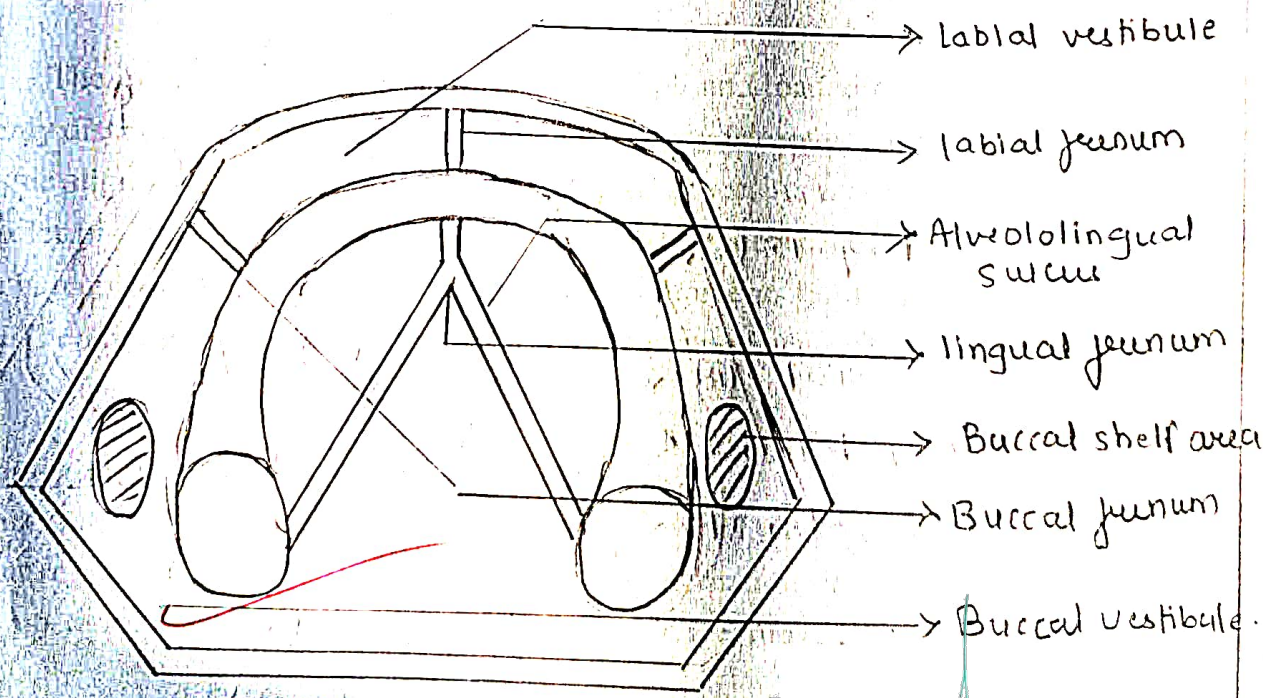


Dr. Harish Kulkarni M.D.S.
 Principal
 T.K.D.C. & Research Centre,
 Jew Pargaon, Tal: Hatkanangle,
 Dist. Kolhapur. 416 137

Maxillary landmark -



Mandibular landmark



Dr. Harish Kulkarni M.D.S.
Principal
T.K.D.C. & Research Centre,
Jew Pargaon, Tal: Hatkanangle,
Dist. Kolhapur. 416 137

CASE HISTORY PROFORMA

Name : Manasingsh Babu Patil Case No : 1
Age : 60 Date of Allotment : 6/4/2024
Occupation : Farmer Receipt No. : 48276
Address : Kasba thane, Tal panhala Payment : 2000/-
Dist. Kolhapur
Telephone No : 8390882438

Name / Address & Tel. of Family Physician : _____

HISTORY

1. Chief Complaint : Patient complains of missing teeth in both upper & lower arch since 2 months

2. Medical history : No relevant history

3. Previous & Present Medication History : No relevant history

4. Patient's Expectations : _____

a) Mastication : Mastication is expected

b) Esthetics : Esthetics is expected

c) Phonetics : Phonetics is expected

d) Others : -

5. Patient's Mental Attitude

a) Philosophical : Patient was co-operative and confident

b) Exacting : -

c) Hysterical : -

d) Indifferent : -

6. Nutritional Status : Balanced / Malnutrition

7. Habits

a) Paan Chewing : No habit

b) Smoking : No habit

c) Others : No habit



8. Dental History : Patient had undergone extraction 2 months ago under LA without any complication

Reason For Loss of Teeth :

a) Maxillary :

1. Caries : Some teeth were grossly decayed
2. Periodontal : Some teeth had mobility with bone loss
3. Congenital : -
4. Others : -

b) Mandibular :

1. Caries : -
2. Periodontal : Bone loss with grade III mobility
3. Congenital : -
4. Others : -

Sequences of Loss of Teeth : Posterior followed by anterior

a) Maxillary : Anterior
Posterior

b) Mandibular : Anterior
Posterior

Duration of Complete Edentulism : 2 month

Number of Previous Dentures Worn : No previous denture

Existing Denture Evaluation : -

Criteria of Evaluation	Maxillary		Mandibular	
	Poor	Average	Good	Excellent
● Retention	Poor	Average	Good	Excellent
● Stability	Poor	Average	Good	Excellent
● Support	Average	Good	Excellent	
● Aesthetic	Average	Good	Excellent	
● Denture Hygiene	Poor	Average	Good	Excellent
● Vertical Relation	Increased	Reduced	Adequate	
● Occlusion	Increased	Reduced	Adequate	

Patient's Comment on Present Dentures :

1. Comfort : Poor / Average / Good / Excellent

2. Chewing Efficiency : Poor / Average / Good / Excellent

3. Aesthetic : Poor / Average / Good / Excellent

4. Speech : Poor / Average / Good / Excellent

5. Others : -

Dr. Harish Kulkarni M.D.S
Principal
K.D.C. & Research Centre
Jaw Pargaon, Tal: Hatkanangle
Dist: Solapur - 416 137

General Examination

1. Gait & Built : Mesomorphic and erect
2. Physical Deformities: No deformities
3. Skin Colour : Dark brown
4. Other :

Extra Oral Examination

1. Facial Symmetry : Symmetrical / Asymmetrical
2. Face Form : Square / Tapering / Square Tapering / Ovoid
3. Facial Profile : Straight / Retrognathic (convex) / Prognathic (concave)
4. Lip : Competent
 - Length : Normal / Long / Short
 - Thickness : Thin / Thick
 - Tonicity : Normal / Hypertonic / Hypotonic
 - Competency : Competent / Incompetent
 - Support : Adequate / Inadequate
5. Nasolabial Fold : Prominent / Not Prominent
6. Temporomandibular Joint :
 - Tenderness / Discomfort
 - Crepitus : Present / Absent
7. Mandibular Movements : Normal
Deviation - No Deviation
8. Neuromuscular Co-ordination : Poor / Average / Good



Dr. Harish Kulkarni M.D.S.
Principal
T. K. D. C. & Research Centre,
Jew Pargaon, Tal: Hatkanangle,
Dist. Kolhapur - 416 137

Intraoral Examination

1. Mucosa :

- a) Buccal : No abnormality detected
- b) Floor of the Mouth : No abnormality detected
- c) Palate - Hard : } No abnormality detected
- Soft : }

2. Tongue Size : Small / Medium / Large

3. Maxillary Arch :

a) Frenal Attachment : (Single / Multiple / Prominent / Not Prominent / Close Crest of ridge)

1. Labial : Single and prominent

2. Buccal :

* Right : Prominent

* Left : Prominent

b) Residual Ridge Contour :

i. Smooth - smooth edge contour

ii. Irregular -

iii. Spiny -

iv. Knife Edged -

v. Undercuts - Present

vi. Flat

vii. Concave

c) Residual Ridge Mucosa :

i. Firm & Resilient ✓

ii. Inflamed

iii. Hyperplastic

iv. Fibrous

d) Incisive papilla : Prominent / Not Prominent ✓

e) Mid Palatine Raphae : Prominent / Not Prominent ✓

f) Arch form : Square / Tapering / Ovoid ✓

g) Arch Size : Large / Medium / Small ✓

h) Palatal Vault Form : High / Medium / Low ✓

i) Soft Palate :

1. Class I ✓

2. Class II

3. Class III

j) Posterior Palatal Seal Area : Normal / Wide ✓

k) Gag Reflex : Normal / Evagerted ✓

l) Maxillary Tuberosity :

1. Bulbous ✓

2. Pendulous

3. Undercuts

: Unilateral / Bilateral



Dr. Harish Kulkarni M.D.S.
Principal
T. K. D. C. & Research Centre,
Jew Pargaon, Tal. Hatkanangle,
Dist. Kolhapur - 416 137

2. Maxillary Torus Palatinus : Class I/II/III absent

3. Mandibular Arch :

a) Frenal Attachment : (Single/Multiple/Prominent/Not Prominent/Close Crest of ridge)

1. Labial : Single and Prominent

2. Lingual : Single

3. Buccal :

* Right : Not prominent

* Left : Single

b) Residual Ridge Contour :

i. Smooth ✓

ii. Irregular -

iii. Spiny -

iv. Knife Edged -

v. Undercuts - present

vi. Flat -

vii. Concave -

c) Residual Ridge Mucosa :

i. Firm & Resilient ✓

ii. Inflamed -

iii. Hyperplastic -

iv. Fibrous ✓

d) Retromolar Pad Area : Pear Shaped / Non Pear Shaped

Resilient / Non Resilient

e) Arch form : Square / Tapering / Ovoid

f) Arch Size : Large / Medium / Small

g) Mylohyoid Ridge : Prominent / Not Prominent / Sharp

h) Genial Tubercle :

i) Torus Mandibulars : Absent

5. Ridge Relationship :

a. Class I (Mesiognathic) ✓

b. Class II (Retrognathic)

c. Class III (Prognathic)

6. Inter - Arch Distance :

7. Saliva :

a. Type : Serous / Mucous / Combination

b. Consistency : Thin / Thick / Rope

8. Pre-extraction Records, if any : -

9. Any Other Findings : No other finding



Radiographic Examination

- 1. O. P. G. : —
 - 2. I. O. P. A. Radiograph : —
 - 3. Lateral Cephalograms : —
 - 4. TMJ Views : —
- Remarks : —

Investigations

- 1. Haematological Investigations : —
- 2. Urine Analysis : —
- 3. Other : —

Diagnosis : False complete anodontia
 Bilaterally edentulous maxillary
 and mandibular arch

Prognosis :

Aesthetics	Average / Excellent
Retention	Average / Excellent
Stability	Average / Excellent
Support	Average / Excellent
Comfort	Average / Excellent

Dr. Mahesh Kulkarni M.D.S.
 J. K. D. C. & Research Centre,
 Jaw Parganah, Tal. Hatkanangle,
 Dist. Kolhapur - 416 007

Treatment Plan

Phase-I

: Pre-Prosthetic Phase NOT required

Phase-II

: Prosthetic Phase Complete denture

Clinical Step	Material	Technique
Preliminary Impression	Impression compound	Mucocompressive
Final Impression	Border moulding green stick Impression - 20E	selective pressure technique
Denture Base	Cold cure & heat cure	sprinkle on method
Jaw Relation Record	Vertical jaw relation modelling wax	Niswanger's method
Selection of Teeth	Acrylic teeth	

Date	Work Done	Specific Problem	Signature
13/5/24	Anterior Try-in		
13/5/24	Posterior Try-in		
14/5/24	Waxing & Carving		
16/5/24	Sealing		
17/5/24	Flasking		
18/5/24	Dewaxing the flask		
19/5/24	Packing and Acrylization		
20/5/24	Deflasking Denture		
23/5/24	Laboratory Remount		
27/5/24	Finishing & Polishing		
25/6/24	Denture Insertion & Instructions		
	Recall		
	Follow-up		

Date of Allotment : 8/4/24

Date of Completion : 25/6/24

Grade :

Signature of Instructor



Department of Prosthodontics and Crown & Bridge



Dr. Harish Kulkarni, M.D.S.
Principal
F.K.D.C. & Research Centre,
Jew Pargaon, Tal: Hatkanangle,
Kolhapur - 416 137

(VII)

REMOVABLE PARTIAL DENTURE RECORD INDEX

S. No.	Date	Patient's Name	Date of Commencement	Date of Completion	Staff Sign.
1	11-4-23	Dilip Patil	11-4-23	24-5-23	
2	9/9/24	Sunil Shankar Nayadne	9/9/24	26/9/24	

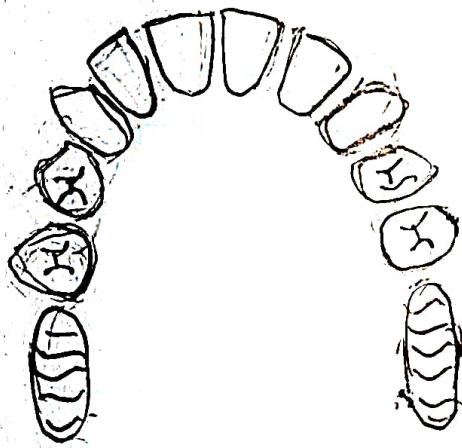



 Dr. Harish Kulkarni M.D.S.
 Principal
 T.K.D.C. & Research Centre,
 Jew Pargaon, Tal: Hatkangangle,
 Dist. Kolhapur. 416 137

Class I

Bilaterally edentulous space located posterior to remaining natural teeth

Kennedy's class I

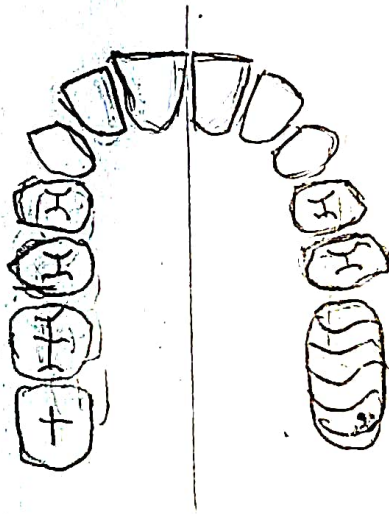


Dr. Harish Kulkarni M.D.S.
Principal
T.K.D.C. & Research Centre,
Jew Pargaon, Tal: Hatkanangle,
Dist. Kolhapur 416 137

Class II

A Unilateral edentulous area located posterior to remaining natural teeth

Kennedy's class II




Dr. Harish Kulkarni M.D.S.
Principal
T. K. D. C. & Research Centre,
Jew Pargaon, Tal: Hatkanangle,
Dist. Kolhapur. 416 137

Class III

A unilateral edentulous area located with natural teeth remaining both anterior & posterior to it

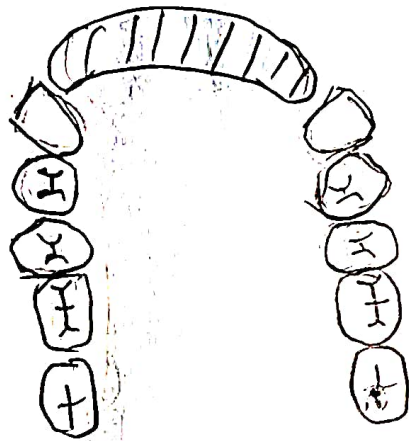
Kennedys class III



Dr. Harish Kulkarni M.D.S.
Principal
T.K.D.C. & Research Centre,
Jew Pargaon, Tal: Hatkanangle,
Kolhapur 416 137

Class IV -

A single but bilateral (crossing the midline) edentulous area located to anterior to remaining natural teeth

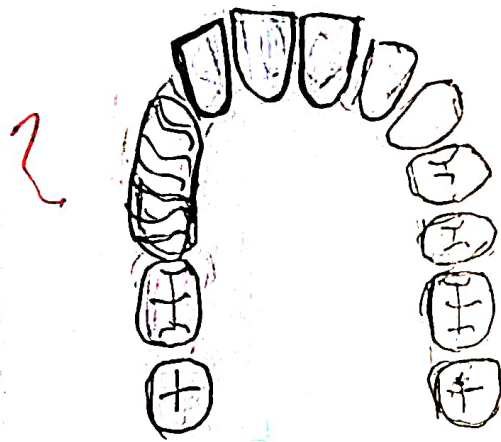


Dr. Harish Kulkarni M.D.S.
Principal
T.K.D.C. & Research Centre,
Jew Pargaon, Tal: Hatkanangle,
Dist. Kolhapur - 416 137

Class II -

Edentulous area bounded anteriorly and posteriorly by natural teeth best in which the anterior abutment (eg lateral incisor) not suitable for support

Kennedys class II

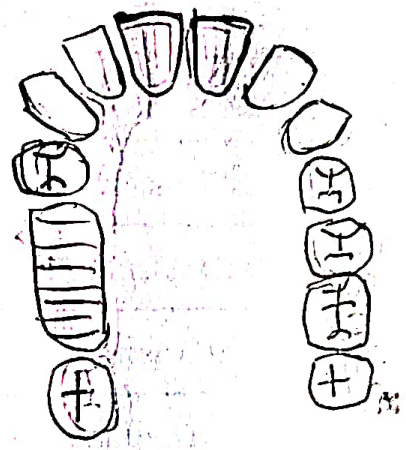


Dr. Harish Kulkarni M.D.S.
Principal
T.K.D.C. & Research Centre,
Jew Pargaon, Tal: Hatkanangle,
Dist. Kolhapur 416 137

class VII

Edentulous areas in which the teeth adjacent to space areas capable of total support of the required prosthesis.

Kennedy's class III



E



Dr. Harish Kulkarni M.D.S.
Principal
T. K. D. C. & Research Centre,
Jew Pargaon, Tal: Hatkanangle,
Dist. Kolhapur. 416 137

DEPARTMENT OF PROSTHODONTICS

Date: 11/4/2023

TREATMENT RECORD FOR PARTIAL DENTURE PATIENTS

Dilip Pahl

Altawde Tal - Hatkanangle Dist - Kolhapur

Farmer

Complaint : Patient complains of missing teeth in lower left back teeth region of jaw since 1 year.

: No relevant history

: Patient has undergone extraction under LA without any complication 1 year back

a) No. of teeth lost : 1

b) Reasons for the loss of teeth : Extraction

c) Edentulous Period : 1 year

d) Individual teeth condition : -

e) Occlusion : Angle's class I maboclusion

f) If old denture wearer : NO

i) Duration of the denture : -

ii) Last Experience-with the denture : -

iii) Reasons for replacing : -

g) Kennedy's classification : Class II Kennedy's Classification

Factors :

h) Motivation : Functional

i) Diet : Mixed

j) Habits : No adverse habit

k) Mental Attitude (House classification) : Class I - philosophical



Dr. Harish Kulkarni M.D.S.
Principal
J.K.S. & Research Centre
Jew Pargaon, Tal: Hatkanangle
Dist: Kolhapur - 416 137

6. Orofacial Examination :

- l) Face Form : Square tapering
- m) Face Profile : class II - retrognathic profile
- n) Lips : Competent
- o) Tongue : class I

7. Hard Palate

: Vault flat

8. Slops of Soft Palate

- : - Gentle
- Medium ✓
- Sharp

9. Residual Ridges

- a) Shape Maxillary - oval arch form
Mandibular - Tapering arch form
- b) Undercuts Bilateral
- c) Surface smooth
- d) Maxillary Tubercity Bulbous
- e) Tori -
- f) Frenum No frenal attachment
- g) Inter Arch Space of Edentulous Areas: Not present

10. Saliva

: Consistency - Thin/Thick ✓
Flow - Reduced / Average / Excessive Not present

11. T.M.J.

: No abnormality detected

12. Oral Mucosa

: Color of mucosa - Pale pink
Condition of mucosa - Class I - Healthy mucosa
Thickness of mucosa - class I

13. Prognosis

: Good

14. Treatment Plan


: Removable Partial Denture

Sign of Staff Incharge

: Dr. [Signature]

Sign of Operator

: _____



DEPARTMENT OF PROSTHODONTICS

Date : 26/9/24

TREATMENT RECORD FOR PARTIAL DENTURE PATIENTS

Sunil Shankar Masadne

Pimpalgaon, Hatkanangle, Kolhapur

Business

Complaint : Patient complains of missing teeth in lower front tooth region of jaw since 6 months.
: No Relevant history
: Patient had undergone extraction under LA without any complication

a) No. of teeth lost

: 6

b) Reasons for the loss of teeth : Decayed tooth (Extraction)

c) Edentulous Period : 6 months

d) Individual teeth condition : -

e) Occlusion

: Angle's class I occlusion.

f) If old denture wearer

: No

i) Duration of the denture

: -

ii) Last Experience-with the denture :

iii) Reasons for replacing :

g) Kennedy's classification

: class II Kennedy's classification

h) Factors

: Esthetic demand

h) Motivation

: Mixed

i) Diet

: Moderate tobacco chewing

j) Habits

: Class I - philosophical

k) Mental Attitude (House classification) :

Dr. Manish Mulkar M.D.S
Principal
C. & Research Centre,
Pimpalgaon, Hatkanangle,
Kolhapur, 416 137

6. Orofacial Examination :

1) Face Form : Square-tapering

m) Face Profile : Class III profile

n) Lips : Competent

o) Tongue : Class I

7. Hard Palate : Vault

Flat

8. Slops of Soft Palate : - Gentle

- Medium ✓

- Sharp

9. Residual Ridges :

a) Shape Maxillary - oval arch form

Mandibular - Tapering arch form

b) Undercuts Bilateral

c) Surface Smooth

d) Maxillary Tubercosity Bulbous

e) Tori -

f) Frenum Gingival

g) Inter Arch Space of Edentulous Areas Not present

10. Saliva

Consistency: Thin/Thick ✓

Flow - Reduced / Average / Excessive ✓

11. T.M.J.

: No abnormality detected

12. Oral Mucosa

: Color of mucosa - Pale pink

Condition of mucosa - class I - Healthy mucosa
Thickness of mucosa - class I

13. Prognosis

: Good

14. Treatment Plan

: Removable (Partial) Denture

Sign of Staff Incharge

Sign of Operator



Dr. Harish Kulkarni M.D.S.
Principal
J.K.D.C. & Research Centre,
New Bazaar, Tal: Hatkanangle,
Dist: Kolhapur - 416 127

