



TATYASAHEB KORE DENTAL COLLEGE AND RESEARCH CENTRE

NEW PARGAON – 416 113

Tal.: Hatkanangale Dist.:Kolhapur (Maharashtra State)

National Dental Commission

INFORMATION REGARDING INSTITUTIONAL COMPLIANCE



4. Clinical Compliance

4.2 Student clinical work registers are updated regularly.

Seat. No.

University Exam No.

Mahatma Gandhi Charitable Medical Trust, Warananagar

**TATYASAHEB KORE DENTAL COLLEGE & RESEARCH CENTRE,
NEW PARGAON**

RECOGNISED BY DENTAL COUNCIL OF INDIA, NEW DELHI

**AFFILIATED TO MAHARASHTRA UNIVERSITY OF
HEALTH SCIENCES, NASHIK**

NAAC ACCREDITED



WARANA
HEALTH MOVEMENT
Est: 1 9 9 2

DEPARTMENT OF PROSTHODONTICS

PROSTHODONTICS

RECORD BOOK

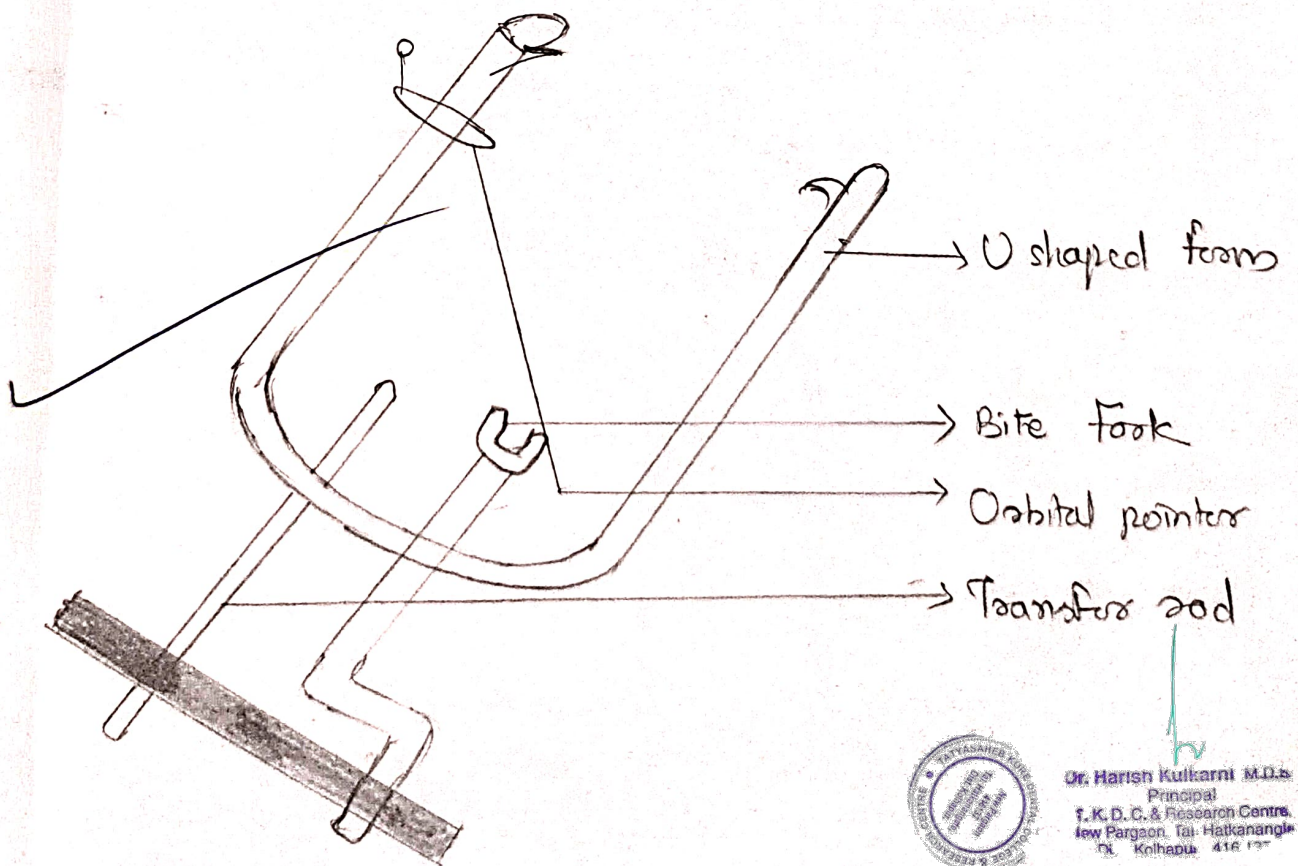
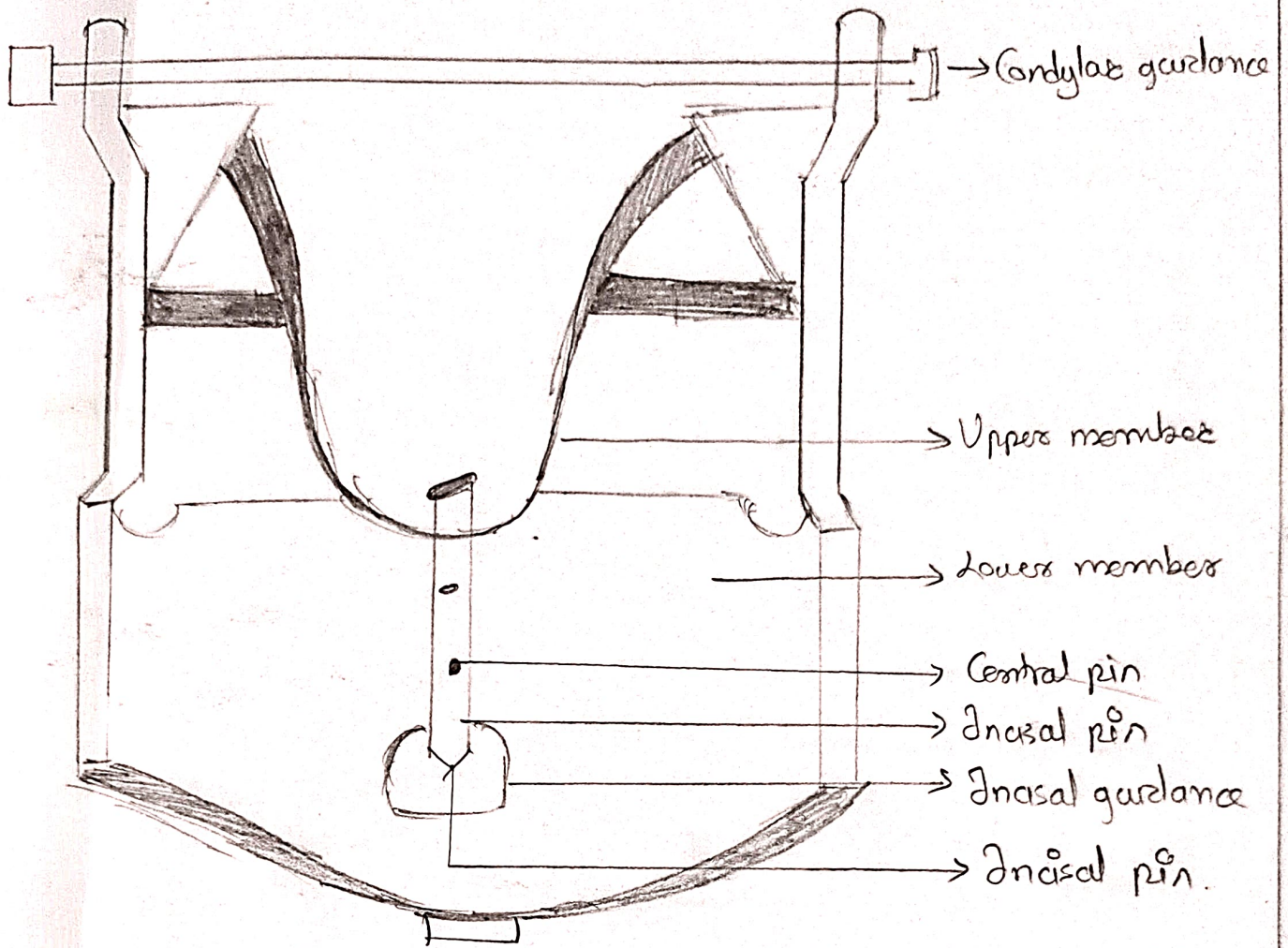
NAME Pratiksha Dinkar Jagdale

CLASS IV BDS ROLL NO. 14

YEAR 2025-26



Dr. Harish Kulkarni M.D.S.
Principal
T.K.D.C. & Research Centre,
New Pargaon, Tal: Hatkanangla,
Dist. Kolhapur. 416 137

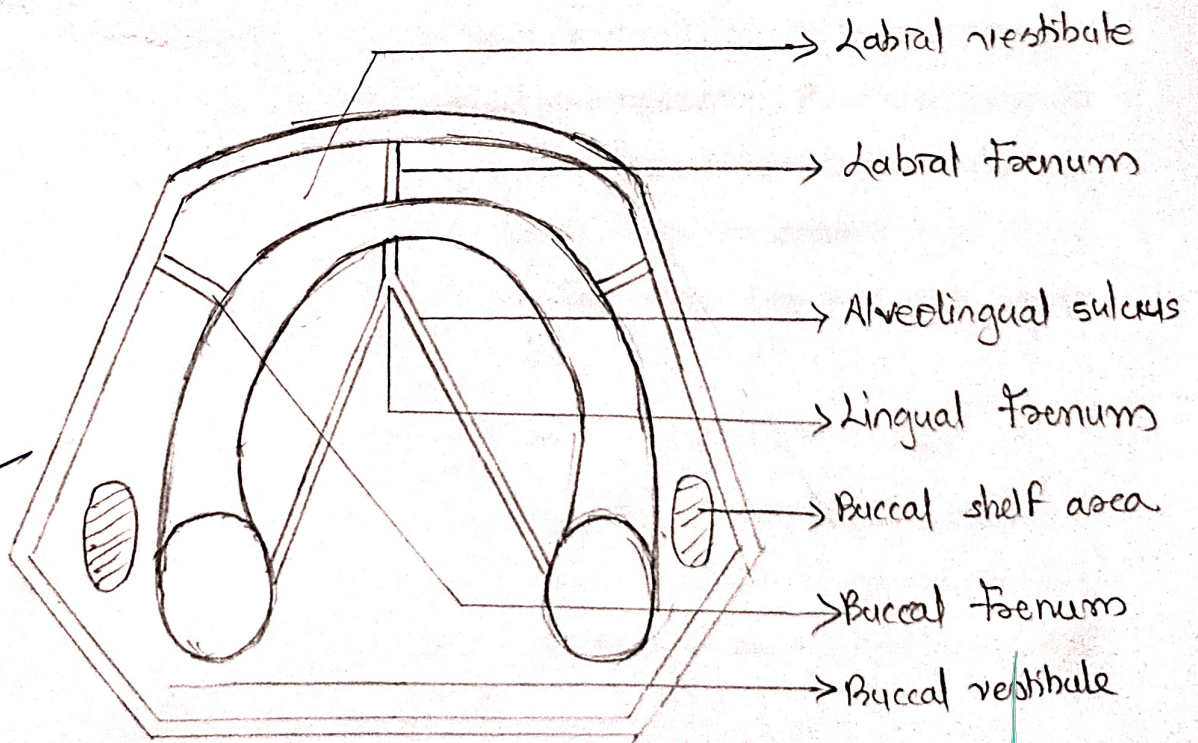
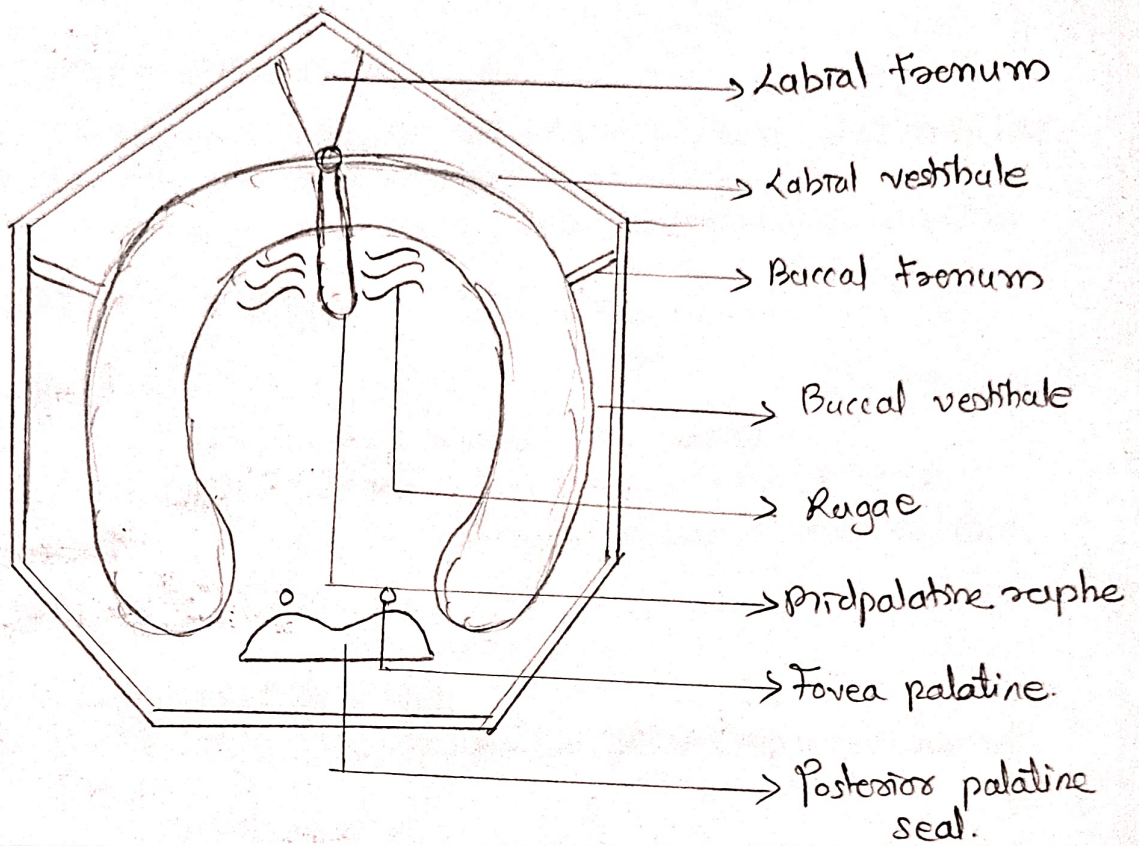


Facebow



Dr. Harish Kulkarni M.D.S.
 Principal
 T.K.D.C. & Research Centre,
 Jew Pargaon, Tal. Hatkanangle,
 Dist. Kolhapur. 416 137

Maxillary Landmark



✓
17/5/26



Dr. Harish Kulkarni M.D.S.
 Principal
 T.K.D.C. & Research Centre,
 Jew Pargan, Tal: Hatkanangle,
 Dist. Kolhapur. 416 137

CASE HISTORY PROFORMA

Name : Surekha Shelake Case No : 95506
Age : 60 Date of Allotment : 23/2/2026
Occupation : Housewife Receipt No. : 92212
Address : Kodoli Payment : 2000/-

Telephone No. : 9561241213

Name/Address & Tel. of Family Physician: _____

HISTORY

1. Chief Complaint Pt do missing teeth in upper & lower arch since 2 months
2. Medical history No relevant history
3. Previous & Present Medication History: No relevant history

4. Patient's Expectations _____

- a) Mastication
- b) Esthetics
- c) Phonetics
- d) Others

5. Patient's Mental Attitude

- a) Philosophical
- b) Exacting _____
- c) Hysterical _____
- d) Indifferent _____

6. Nutritional Status : Balanced/Malnutrition

7. Habits

- a) Pan Chewing Absent
- b) Smoking Absent
- c) Others Absent

(1)



Dr. Harish Kulkarni M.D.S.
Principal
T.K.D.C. & Research Centre,
Jew Pargaon, Tal. Hatkanangle,
Dist. Kolhapur. 416 137

8. Dental History Pt had undergone dental extraction under GA without any complication

Reason For Loss of Teeth: _____

a) Maxillary :

1. Caries :

2. Periodontal :

3. Congenital : _____

4. Others : _____

b) Mandibular :

1. Caries :

2. Periodontal :

3. Congenital : _____

4. Others : _____

Sequences of Loss of Teeth : mandibular anterior > maxillary anterior

a) Maxillary: Anterior
Posterior

b) Mandibular: Anterior
Posterior

Duration of Complete Edentulism : 10 years

Number of Previous Dentures Worn: 1

Existing Denture Evaluation : _____

Criteria of Evaluation	Maxillary	Mandibular
• Retention	Poor/Average/Good/Excellent	Poor/Average/Good/Excellent
• Stability	Poor/Average/Good/Excellent	Poor/Average/Good/Excellent
• Support	Average/Good/Excellent	Average/Good/Excellent
• Esthetics	Average/Good/Excellent	Average/Good/Excellent
• Denture Hygiene	Poor/Average/Good/Excellent	Poor/Average/Good/Excellent
• Vertical Relation	Increased/Reduced/Adequate	Increased/Reduced/Adequate
• Occlusion		

Patient's Comment on Present Dentures :

1. Comfort : Poor/Average/Good/Excellent
2. Chewing Efficiency : Poor/Average/Good/Excellent
3. Esthetics : Poor/Average/Good/Excellent
4. Speech : Poor/Average/Good/Excellent
5. Others : _____

(II)



Dr. Harish Kulkarni M.D.S.
Principal
T.K.D.C. & Research Centre,
Jew Pargaon, Tal. Hatkanangli,
Dist. Kolhapur. 416 137

General Examination

1. Gait & Built : Ectomorphic, normal
2. Physical Deformities : Absent
3. Skin Colour : Dark
4. Other : _____

Extra Oral Examination

1. Facial Symmetry : ✓ Symmetrical/Asymmetrical
2. Facial Form : ✓ Square/Tapering/Square Tapering/Ovoid
3. Facial Profile : Straight/Retrognathic (convex)/Prognathic (concave)
4. Lips : ✓ Competent
- Length : Normal/Long/Short
- Thickness : ✓ Thin/Thick
- Tonicity : ✓ Normal/Hypertonic/Hypotonic
- Competency : ✓ Competent/Incompetent
- Support : ✓ Adequate/Inadequate

5. Nasolabial Fold : ✓ Prominent/Not Prominent

6. Temporomandibular Joint:

Tenderness/Discomfort Absent

Crepitus: Present/Absent Absent

7. Mandibular Movements : Normal ✓
Deviation

8. Neuromuscular Co-ordination: Poor/Average/Good ✓



Intraoral Examination

1. Mucosa:

- a) Buccal : No abnormality detected
- b) Floor of the Month : No abnormality detected
- c) Palate Hard : No abnormality detected
- Soft : No abnormality detected

2. Tongue Size: Small/Medium/Large

3. Maxillary Arch:

a) Frenal Attachment: (Single/Multiple/Prominent/Not Prominent/ Close Crest of ridge)

- 1. Labial : Single prominent
- 2. Buccal :
 - * Right : Prominent
 - * Left : Prominent

b) Residual Ridge Contour :

- i. Smooth ✓
- ii. Irregular
- iii. Spiny
- iv. Knife Edged
- v. Undercuts ✓
- vi. Flat
- vii. Concave

c) Residual Ridge Mucosa :

- i. Firm & Resilient ✓
- ii. Inflamed
- iii. Hyperplastic
- iv. Fibrous

d) Incisive papilla : Prominent/Not Prominent ✓

e) Mid Palatine Raphe : Prominent/Not Prominent

f) Arch form : Square/Tapering/Ovoid ✓

g) Arch Size : Large/Medium/Small ✓

h) Palatal Vault Form : High/Medium/Low ✓

i) Soft Palate :

- 1. Class I ✓
- 2. Class II
- 3. Class III

j) Posterior Palatal Seal Area ✓

k) Gag Reflex : Normal/Wide ✓

l) Maxillary Tuberosity : Normal/Exaggerated ✓

- 1. Bulbous ✓
- 2. Pendulous
- 3. Undercuts

: Unilateral/Bilateral ✓



2. Maxillary Torus Palatinus : Class I/II/III Absent

3. Maxillary Arch.

a) Frenal Attachment: (Single/Multiple/Prominent/Not Prominent/Close to crest of ridge)

1. Labial : Single prominent

2. Lingual : Single prominent

3. Buccal :

* Right : mucosal not prominent

* Left :

b) Residual Ridge Contour:

1. Smooth ✓

ii. Irregular

iii. Spiny

iv. Knife Edged

v. Undercuts ✓

vi. Flat

vii. Concave

c) Residual Ridge Mucosa :

i. Firm & Resilient ✓

ii. Inflamed

iii. Hyperplastic

iv. Fibrous

d) Retromolar Pad Area : Pear Shaped/Non Pear Shaped
Resilient/Non Resilient

e) Arch form : Square/Tapering/Ovoid

f) Arch Size : Large/Medium/Small

g) Mylohyoid Ridge : Prominent/Not Prominent/Sharp

h) Genial Tubercle : Absent

i) Torus Mandibularis : Absent

5. Ridge Relationship :

a. Class I (Mesiognathic) ✓

b. Class II (Retrognathic)

c. Class III (Prognathic)

6. Inter-Arch Distance :

7. Saliva :

a. Type : Serous/Mucous/Combination ✓

b. Consistency : Thin/Thick/Roepy

8. Pre-extraction Records, if any : -

9. Any Other Findings : -

(V)



Dr. Harish Kulkarni M.D.S.
Principal
T.K.D.C. & Research Centre,
New Pargaon, Tal. Hatkanangale,
Dist. Kolhapur. 416 137

Radiographic Examination

- 1. O.P.G : _____
- 2. I.O.P.A. Radiograph : _____
- 3. Lateral Cephalograms : _____
- 4. TMJ Views : _____

Remarks : _____

Investigations

- 1. Hematological Investigations : _____
- 2. Urine Analysis : _____
- 3. Other : _____

Diagnosis : Complete maxillary - mandibular
edentulous residual alveolar
ridge & partial maxillary
residual alveolar ridge.

Prognosis :

Esthetics	✓ Average/Excellent
Retention	✓ Average/Excellent
Stability	✓ Average/Excellent
Support	✓ Average/Excellent
Comfort	✓ Average/Excellent



Treatment Plan


Phase-I

: Pre-Prosthetic Phase *Not required*

Phase-II

: Prosthetic Phase *required.*

Clinical Step	Material	Technique
Preliminary Impression	Impression compound	mucos-compressive
Final Impression	Border moulding Green stick	segmental selective pressure
Denture Base	Cold cure	Spankle on
Jaw Relation Record	modelling wax occlusal rims	
Selection of Teeth	Acrylic teeth	

Date	Work Done	Specific Problem	Signature
23/3/26	Anterior Try-in		
23/3/26	Posterior Try-in		
23/3/26	Waxing & Carving		
24/3/26	Sealing		
24/3/26	Flasking		
24/3/26	Dewaxing the flask		
25/3/26	Packing and Acrylization		
25/3/26	Deflasking Denture		
	Laboratory Remount		
27/3/26	Finishing & Polishing		
28/3/26	Denture Insertion & Instructions		
6/4/26	Recall		
15/4/26	Follow-up		

Date of Allotment : 23/2/26

Date of Completion : 28/3/26

Grade :

E.M. Kulkarni

Signature of Instructor

Department of Prosthodontics and Crown & Bridge

(VII)

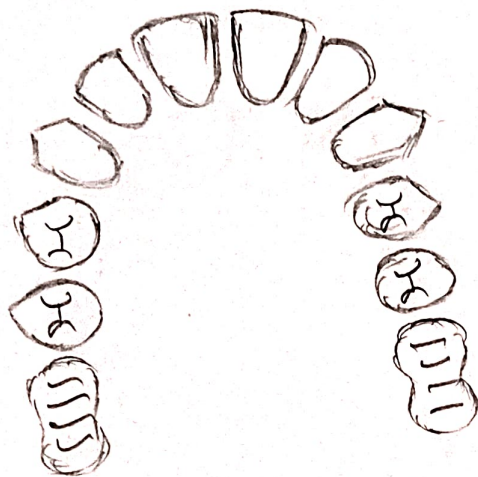


Dr. Harish Kulkarni M.D.S.
Principal
F.K.D.C. & Research Centre,
Jew Pargaon, Tal. Hatkanangle,
Dist. Kolhapur. 416 137

Class I

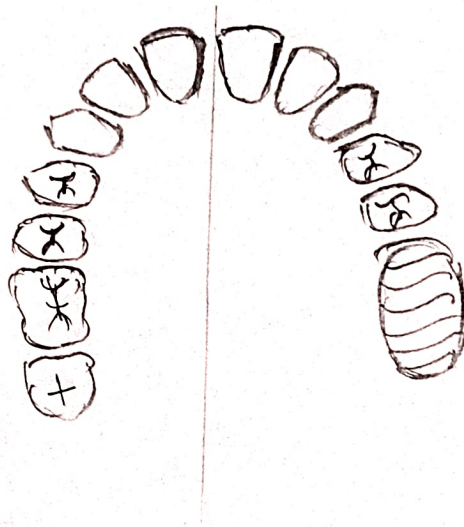
Bilaterally edentulous space located posterior to remaining natural teeth

Kennedy's class I



Class II

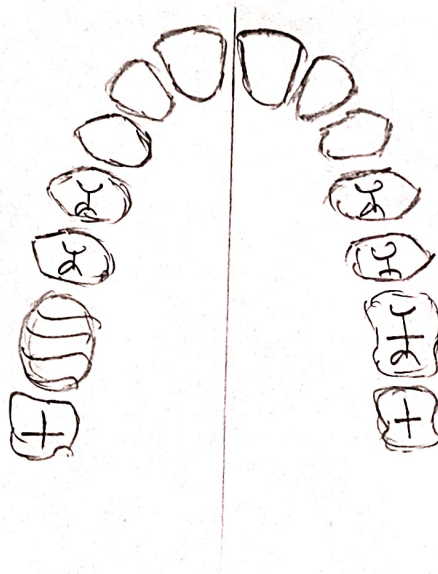
A unilateral edentulous area located posterior to remaining natural teeth.



Class III


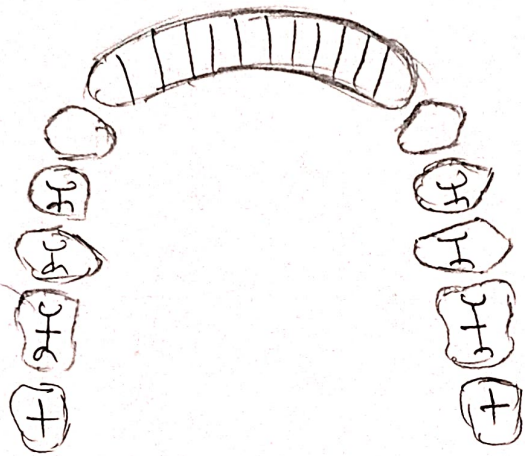
A unilateral edentulous area located with natural teeth remaining both anterior & posterior to it.

Kennedy's Class III



Class IV -

A single but bilateral (Crossing the midline)
edentulous area located to anterior to remaining
natural teeth.

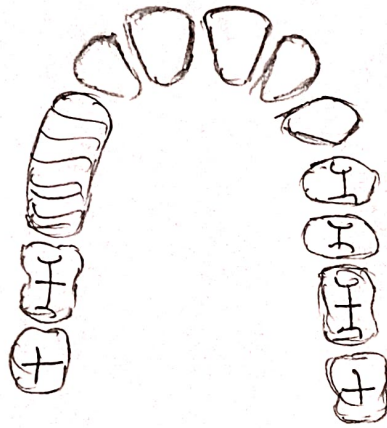


Dr. Harish Kulkarni M.D.S.
Principal
T.K.D.C. & Research Centre,
Jew Pargaon, Tal. Hatkanangale,
Dist. Kolhapur. 416 137

Class V -

Edentulous area bounded anteriorly and posteriorly by natural teeth best in which the anterior abutment (eg. lateral incisors) not suitable for support.

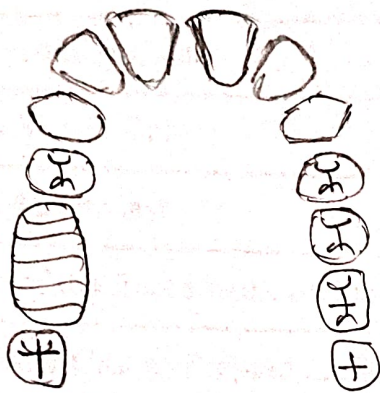
Kennedy's class V



Class VI

Edentulous area in which the teeth adjacent to space area capable of total support of the required prosthesis.

Kennedy's class VI



E

17/4/26



DEPARTMENT OF PROSTHODONTICS

Date: 29/09/2025

TREATMENT RECORD FOR PARTIAL DENTURE PATIENTS

Name : Asma Sayyad

Address : Kasba Bawada, Kolhapur

Occupation : Housewife

1. Chief Complaint : Pt c/o missing teeth in lower left ^{back} region of jaw since 5 months

2. History : No Relevant History

3. Medical : No Relevant History

4. Dental : _____

a) No. of teeth lost : Four

b) Reasons for the loss of teeth : Dental caries

c) Edentulous Period : 5 months

d) Individual teeth condition : _____

e) Occlusion : Class I molar relationship

f) If old denture wearer : No

i) Duration of the denture : 1

ii) Last Experience with the denture: _____

iii) Reasons for replacing : _____

g) Kennedy classification : _____

5. General Factors :

h) Motivation : Good oral health

i) Diet : mixed

j) Habits : No

k) Mental Attitude (House classification) : Philosophical



Dr. Harish Kulkarni M.D.
Principal
T.K.D.C. & Research Centre,
Jew Pargan, Tal. Hatkanangle,
Dist. Kolhapur. 416 137

6. Orofacial Examination : _____
- D Face Form : Symmetrical
- m) Face Profile : Straight
- n) Lips : Competent
- o) Tongue : medium
7. Hard Palate : Vault
8. Slopes of Soft Palate : Gentle
- Medium
- Sharp
9. Residual Ridges : _____
- a) Shape _____
- b) Undercuts _____
- c) Surface _____
- d) Maxillary Tuberosity _____
- e) Tori _____
- f) Frenum _____
- g) Inter Arch Space of Edentulous Areas _____
10. Saliva : Consistency-Thin/~~Thick~~
Flow-Reduced/~~Average~~/Excessive
11. T.M.J. : No tenderness, No clicking sound
12. Oral Mucosa : No relevant history
13. Prognosis : Good prognosis
14. Treatment Plan : Removable Partial Denture
- Sign of Staff In-charge : R
- Sign of Operator : _____

